

## CASE REPORT

## *Scedosporium apiospermum* Otomycosis in an Immunocompetent Man

Santosh Shankar Patil<sup>1\*</sup>, Sunanda A. Kulkarni<sup>1</sup>, Usha Subhod Udgaonkar<sup>1</sup> and Vishal Kishor Magdum<sup>2</sup>

<sup>1</sup>Department of Microbiology, Bharati Vidyapeeth University, Medical College and Hospital, Wanlesswadi, Dist: Sangli, Maharashtra, India and <sup>2</sup>Department of E.N.T., Bharati Vidyapeeth University, Medical College and Hospital, Wanlesswadi, Dist: Sangli, Maharashtra, India

**Abstract:** Otitis externa caused by *Scedosporium apiospermum* is extremely rare. Neglect or delayed management may lead to serious sequel. We report a case of *Scedosporium apiospermum* external otitis in an immunocompetent patient. The patient was treated topically with itraconazole and achieved a clinical and mycological cure.

**Key words:** Otitis externa, *Scedosporium apiospermum*.

### Introduction

Otomycosis, also known as otitis externa, is a fungal infection of external auditory canal. Factors predisposing to infection of the external auditory canal range from existing diseases, such as seborrhoeic dermatitis, eczema, psoriasis, trauma and climatic conditions [1]. Rarely, infection may result in an acute and severe destructive process with subsequent invasion of adjacent tissue. The main fungi responsible for this condition are *Aspergillus*, *Candida* species and whole range of different environmental fungi including *Scedosporium apiospermum* [2]. *S. apiospermum* is an asexual state of teleomorph *Pseudallescheria boydii*, which is homothallic fungus. It is a saprophytic fungus found worldwide in soil and polluted water [3]. But more recently it has emerged as an opportunistic pathogen causing various infections in human beings. Majority of infections due to *S. apiospermum* results in mycetoma. Other infections are localized to paranasal sinuses, lunges, joints, brain, prostate and disseminated infections [3]. Otitis externa caused by *S. apiospermum* is extremely rare.

### Case History

A non diabetic, immunocompetent, 37 years old man presented with a six months history of right sided otalgia and otorrhoea, which had been unresponsive to frequent ear toilet, topical antibiotics and a course of oral amoxicillin. The patient presented with itching, irritation, discomfort, pain and discharge from right external auditory canal. These manifestations were unilateral. Otoscopic examination revealed, erythematous external auditory meatus and black fuzzy growth on cerumen with debris in canal. Routine hematological and blood parameters were normal. Patient was HIV non reactive by HIV Tridot and ELISA. There was no history of any trauma or preexisting disease of right ear external canal. For microbiological examination,

swab was collected under aseptic condition and transported to the laboratory immediately in sterile container. Gram staining of sample revealed, pus cells, gram positive cocci arranged singly and branching septate hyphae. Sample was inoculated on blood agar and Mac Conkey's agar for routine bacterial culture and also on Sabourauds Dextrose Agar (SDA) for fungal culture. Routine bacterial culture was sterile, after 48 hours of aerobic incubation. However on SDA after four days of aerobic incubation, cottony, fluffy, white colony developed, that rapidly turned mousy grey, velvety, with short aerial hyphae. (Fig. 1) Reverse side of the media was initially pale in color which rapidly developed into brownish to black areas. Lactophenol cotton blue mount of the colony showed numerous single celled, pale brown conidia borne singly and in small groups on elongate, simple and branched conidiophores or laterally on hyphae. Conidia were smooth, lemon shaped, oval, with flat base and thick walled. (Fig. 2) The isolate was identified as *Scedosporium apiospermum*, teleomorph (sexual form) *Pseudallescheria boydii*.

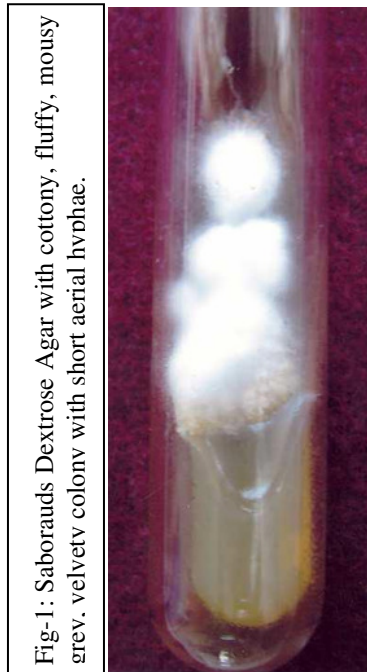


Fig-1: Sabourauds Dextrose Agar with cottony, fluffy, mousy grey, velvety colony with short aerial hyphae.

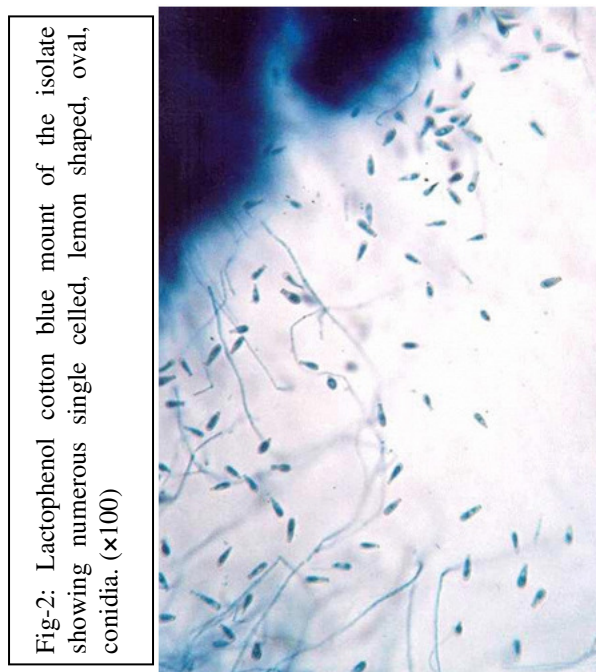


Fig-2: Lactophenol cotton blue mount of the isolate showing numerous single celled, lemon shaped, oval, conidia. (x100)

### Discussion

*Scedosporium apiospermum* is an uncommon laboratory isolate. More recently it has emerged as a pathogen in both immunocompromised and non-immunocompromised patients. *Scedosporium* infection may involve almost any organ [3]. Reports of *S. apiospermum* include invasive pulmonary disease, sinusitis, brain abscess, endocarditis, osteomyelitis, fungemia, etc [2-4]. Otitis externa caused by *S. apiospermum* is extremely rare. Clinical signs of infections are typically similar to those produced by *Aspergillus* or *Fusarium* [3].

Therefore correct laboratory diagnosis is of importance. A five year review in Northern England included 3 patients with otitis who had polymicrobial culture, including *P. boydii* [5]. Zelia Braz et al reported only one case of *S. apiospermum* otitis externa, in their six year retrospective study on otomycosis [1]. In immunocompetent patients, *S. apiospermum* infection tends to be more localized where as on the contrary in the immunocompromised host *S. apiospermum* usually results in a rapidly disseminated infection, that are almost universally fatal. Yao and Messner diagnosed malignant otitis externa caused by *S. apiospermum* in AIDS patient [6]. Otitis media and externa by *S. apiospermum* was diagnosed in an immunocompetent woman who had symptoms of chronic otomastoiditis and otorrhoea [7]. In the present case there was no history of any predisposing factor and patient was immunologically competent. Early diagnosis is very much important especially in case of *S. apiospermum* otitis externa because most case reports of *S. apiospermum* brain abscess in immunocompetent patients have documented CSOM to be the risk factor [3-4]. 40% brain abscesses are associated with otitis media and mastoiditis [4]. Neglect or delayed management of otitis externa may lead to serious sequel. Intracranial complication is serious threat as was seen in few cases [4, 8]. Central nervous system infections are notoriously difficult to treat and are fatal. High mortality rate of CNS infection is may be due to delay in diagnosis. [4, 8]. The present case was managed by local toilet including debridement and intensive cleansing. Topical itraconazole treatment was started immediately and patient responded well to the treatment. Early diagnosis, prompt antifungal treatment and debridement with intensive cleansing have had better prognosis in our patient. It is important to identify the causal agent of otomycosis in order to use appropriate treatment. It is also recommended that the antimycotic treatment chosen should be based on susceptibility of the identified species [9]. Therapeutic choices are very limited in *S. apiospermum* infection. [9] Interestingly this fungus is resistant to amphotericin B in vitro and treatment failure have been widely reported [8-9]. Itraconazole and miconazole both show some activity in vivo and have been used clinically with degree of success as was seen in the present case. The present case highlights the importance of early diagnosis and documentation of rarely encountered *Scedosporium apiospermum* otitis externa infection.

### Acknowledgment

We thank Dr. Arunaloke Chakarabarty, Professor, Department of Mycology, Postgraduate Institute of Medical Education and Research, (PGIMER), Chandigarh, India, for confirming the identification of the isolate.

### References

1. Zelia Braz Vieira da Silva Ponts, Anna Debora Ferreira Silva, Edeltrudes de Oliveira Lima Otomycosis: a retrospective study. *Braz J Otorhinolaryngol.* 2009;75(3):367-70.
2. Chander J. A text book of Medical Mycology 3rd ed. Chapter 28. *Mehta Publishers*, New Delhi 2009;418-21.

3. Josep Guarro J, A Serda Kantarcioglu, Regine Horre, Juan Luis Rodriguez-tudela, Manuel Cuenca Estrella, Juan Berenguer, et al. *Scedosporium apiospermum*: changing clinical spectrum of a therapy-refractory opportunist. *ISHAM, Medical Mycology* 2006;44:295-327
4. Acharya A, Ghimire A, Khanal B, Bhattacharya S, Kumari N, Kanungo R. Brain abscess due to *Scedosporium apiospermum* in a non immunocompromised child. *Indian J Med Microbiol* 2006;24:231-232
5. Milne LJR, Mckerrow WS, Paterson WD. Pseudallescheriasis in northern Br *J Med Vet Mycology* 1986;24:377-382
6. Yao M, Messener AH. Fungal malignant otitis externa due to *Scedosporium apiospermum*. *Ann Otol Rhinol Laryngol* 2001;110:377-389.
7. Baumgartner BJ, Rakita RM, Backous DD. *Scedosporium apiospermum* otomycosis. *Am J Otolaryngol* 2007;28:254 -256
8. Koh, Jarrod, Holland, Juliette. Necrotising external otitis caused by the fungus *Pseudallescheria boydii*. *Austr J Oto-laryngol* 1998;10:377-389.
9. Raymundo Munguia, Sam J. Daniel. Otological antifungals and otomycosis: A review. *Int J Pediatr Otorhinolaryngol* 2008;72:453-459

\*All correspondences to: Santosh Shankar Patil, Asst. Professor, Department of Microbiology, Bharati Vidyapeeth University , Medical College and Hospital, Wanlesswadi, Sangli, Dist: Sangli Maharashtra India. Pin Code: 416416 E mail: micro\_santosh@yahoo.co.in